

ADVANCES IN
Cancer
IMMUNOTHERAPY™



Management and Mitigation of irAEs for Immunotherapy Prescribers

David F. McDermott M.D.

Beth Israel Deaconess Medical Center

Dana Farber Harvard Cancer Center

Harvard Medical School



Society for Immunotherapy of Cancer

Disclosures

- Consultant: Bristol-Myers Squibb, Pfizer, Merck, Eisai Co., Ltd., Genentech, Inc., Novartis AG, Array BioPharm, Exelixis
- Kidney Cancer Research: Prometheus Laboratories.



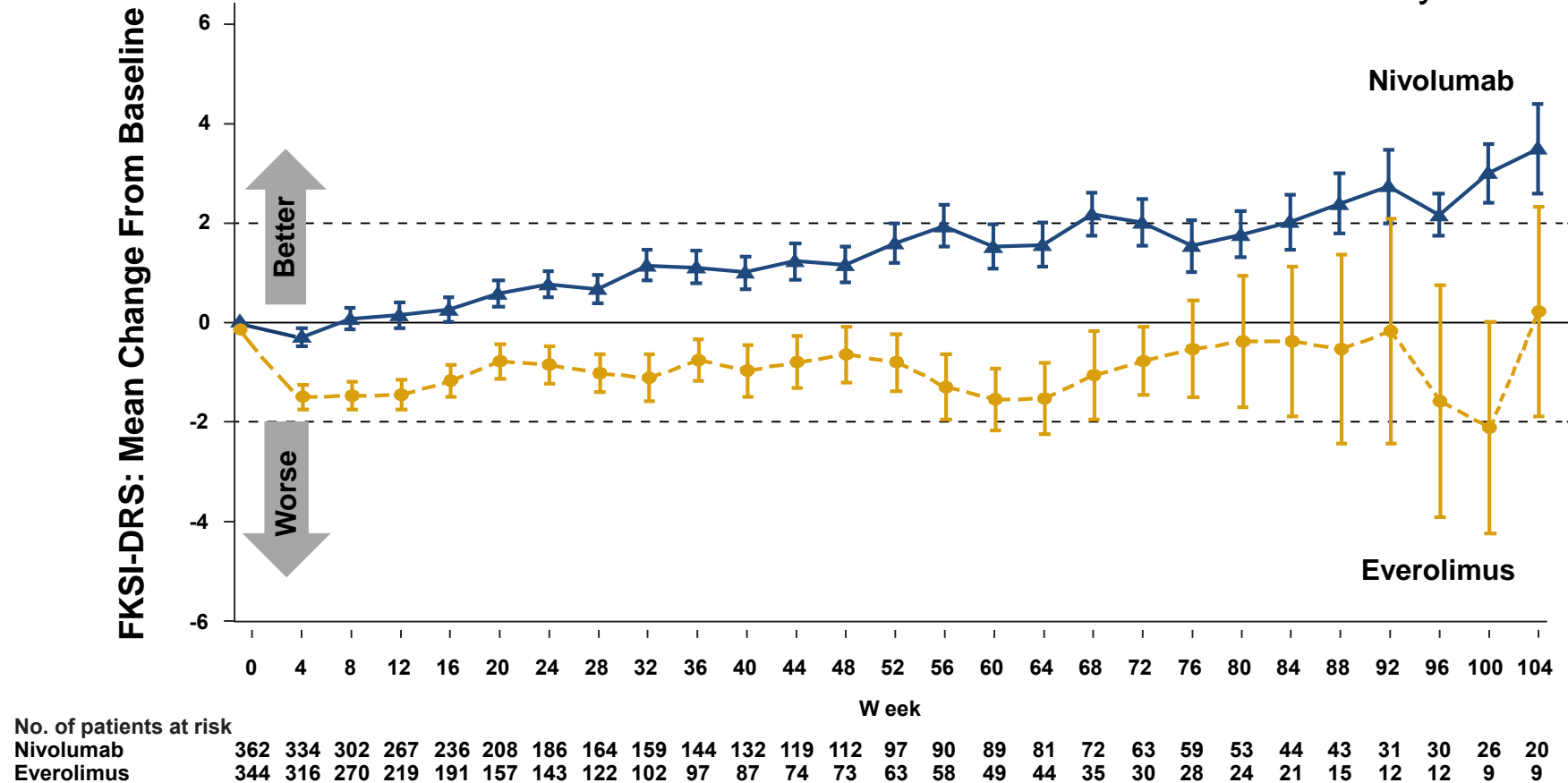
ORIGINAL ARTICLE

Nivolumab versus Everolimus in Advanced Renal-Cell Carcinoma

R.J. Motzer, B. Escudier, D.F. McDermott, S. George, H.J. Hammers, S. Srinivas, S.S. Tykodi, J.A. Sosman, G. Procopio, E.R. Plimack, D. Castellano, T.K. Choueiri, H. Gurney, F. Donskov, P. Bono, J. Wagstaff, T.C. Gaurer, T. Ueda, Y. Tomita, F.A. Schutz, C. Kollmannsberger, J. Larkin, A. Ravaud, J.S. Simon, L.-A. Xu, I.M. Waxman, and P. Sharma, for the CheckMate 025 Investigators*

Change from baseline in quality of life scores on FKSI-DRS

- A clinically meaningful and statistically significant improvement in QoL was seen with nivolumab versus everolimus for the duration of the study



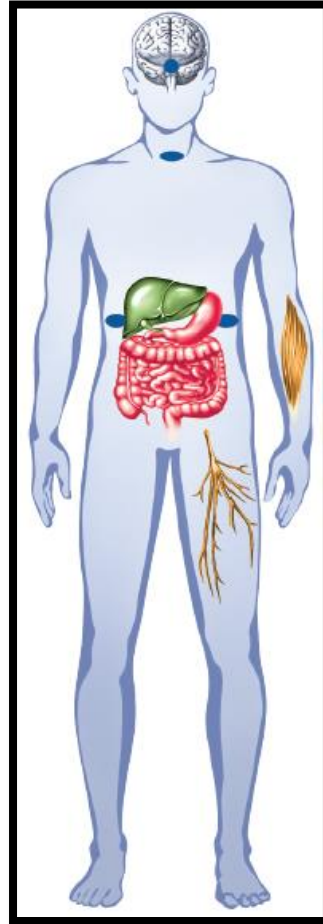
Questionnaire completion rate: ≥80% during the first year of follow-up



Toxicity with immunotherapy agents

Activation of the immune system against tumors can result in a novel spectrum of immune-related Adverse Events (**irAEs**)

- May be due to cytokine release by activated T cells
- May be unfamiliar to clinicians
- Requires a multidisciplinary approach
- Can be serious
- Requires prompt recognition and treatment
- Requires patient and HCP education



irAEs occur in certain organ systems:

- Skin
- Endocrine system
- Liver
- Gastrointestinal tract
- Nervous system
- Eyes
- Respiratory system
- Hematopoietic cells
- Musculoskeletal

Treatment-related AEs occurring in ≥10% of patients in either arm

Event	Nivolumab N = 406		Everolimus N = 397	
	Any grade	Grade 3 or 4	Any grade	Grade 3 or 4
Treatment-related AEs, %	79	19	88	37
Fatigue	33	2	34	3
Nausea	14	<1	17	1
Pruritus	14	0	10	0
Diarrhea	12	1	21	1
Decreased appetite	12	<1	21	1
Rash	10	<1	20	1
Cough	9	0	19	0
Anemia	8	2	24	8
Dyspnea	7	1	13	<1
Edema peripheral	4	0	14	<1
Pneumonitis	4	1	15	3
Mucosal inflammation	3	0	19	3
Dysgeusia	3	0	13	0
Hyperglycemia	2	1	12	4
Stomatitis	2	0	29	4
Hypertriglyceridemia	1	0	16	5
Epistaxis	1	0	10	0

PD-1 Pathway Blockade Based ImmunoRx: Unanswered Questions

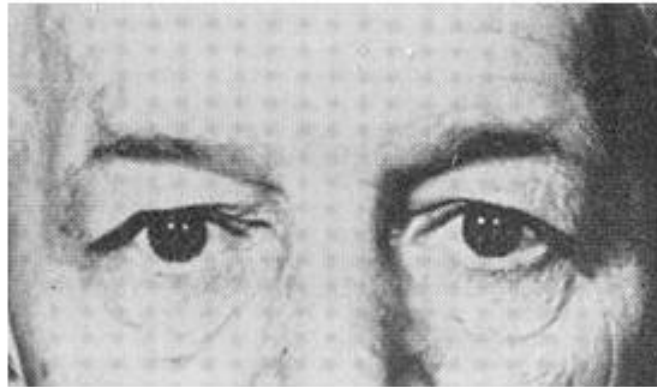
- **Will toxicity management prove challenging?**
 - **Will rare but serious toxicities occur?**
 - Will late toxicity emerge?
 - Will certain toxicities make combinations difficult?
 - Will history of autoimmunity limit application?

Case Study #1

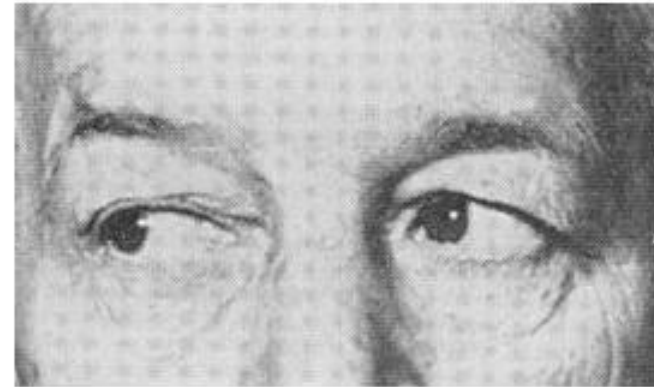
- A 66-year-old male previously treated mRCC enrolled in a clinical trial of anti-PD-L1 Ab therapy
- Approximately two weeks after his second dose of anti-PD-L1 antibody, he presented with sudden onset of double vision, along with a 10-day history of muscle pain and weakness, joint aches and generalized malaise.
- Neurologic exam was notable for near complete ophthalmoplegia, fatigability of his deltoids, otherwise non-focal. Labs were notable for transaminitis and myositis.



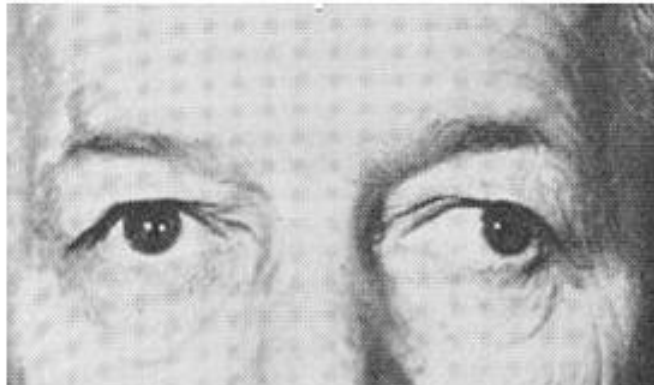“Look at me”



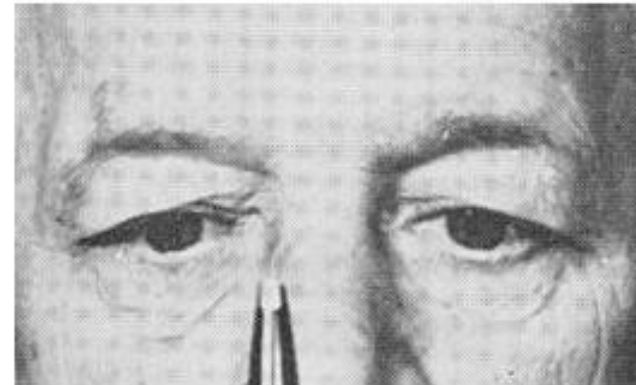“Look to the right”



“Look to the left”



“Look at this object”



Case Description: 65-Year-Old Male (continued)

- This patient was diagnosed with drug-induced myasthenia gravis by serologic testing:
 - Antibody titer detected in pretreatment sample at lower level.

Case Description: 65-Year-Old Male (continued)

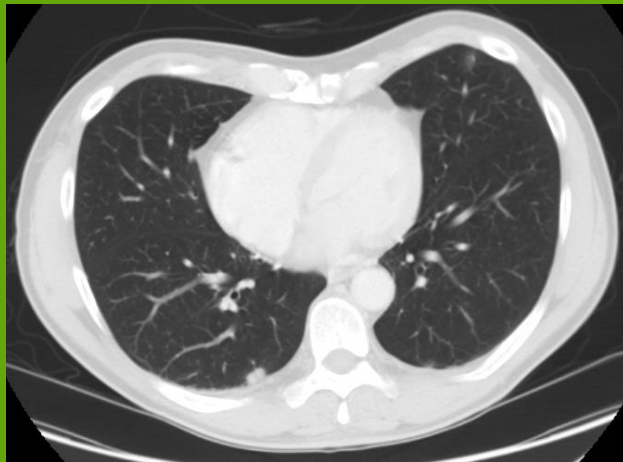- Neurologic symptoms resolved on steroids.
- Patient was taken off study, then developed disease progression three months later.
- Patient subsequently received VEGF TKI therapy.



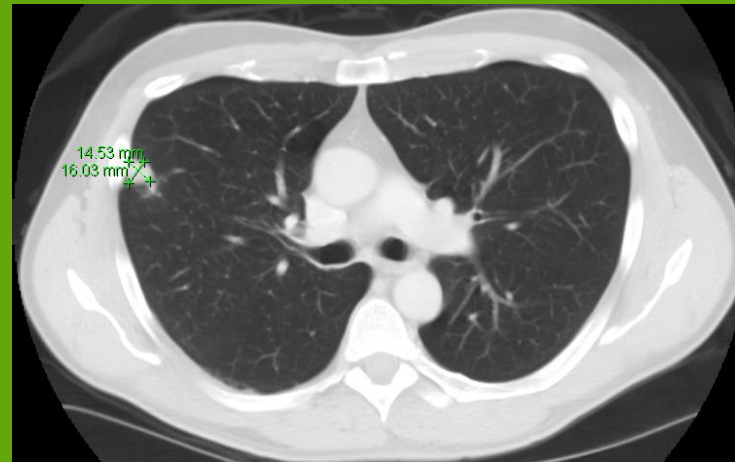
Case Study #2

- A 56-yr-old male with stage 4 RCC was treated with high dose IL-2
- After progression, he was enrolled in clinical trial for nivolumab at 3 mg/kg
 - Patient developed a dry cough and came in for an exam

Scan at Mo 6



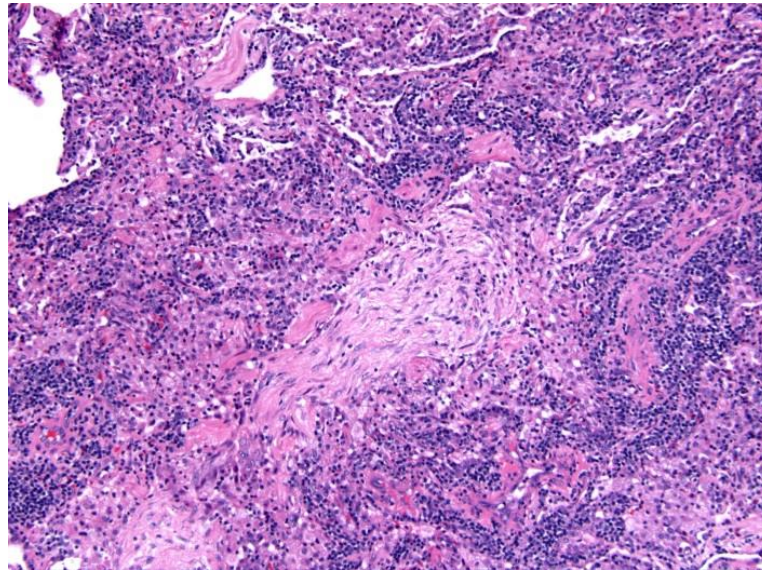
Subsequent Scan at Mo 8





Case Study #2

- Patient underwent biopsy to confirm disease progression
 - Biopsy suggested bronchiolitis obliterans



Patient underwent biopsy to confirm disease progression, and the biopsy suggested bronchiolitis obliterans.

How would you manage this patient?

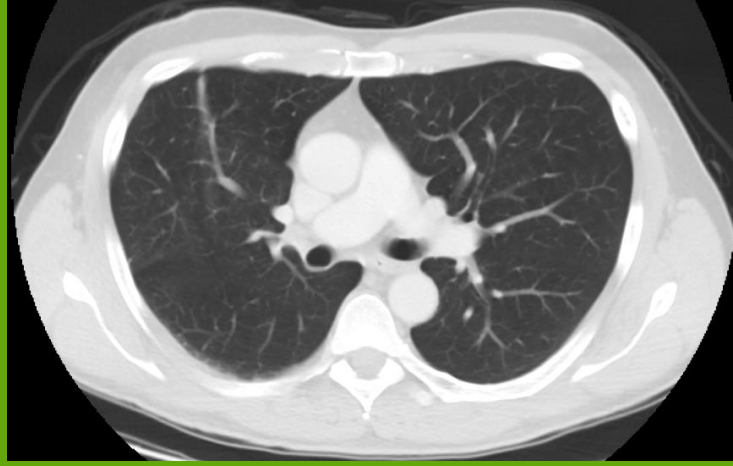1. Continue nivolumab and start steroid treatment.
2. Continue nivolumab and start broad-spectrum antibiotics.
3. Discontinue nivolumab and start steroid treatment.
4. Discontinue nivolumab and start broad-spectrum antibiotics.



Case Study #2

- Symptoms and lung lesions resolved with initiation of steroid therapy
- Nivolumab treatment was discontinued, and disease is currently stable off all therapy x two years

Lung Lesions Resolved



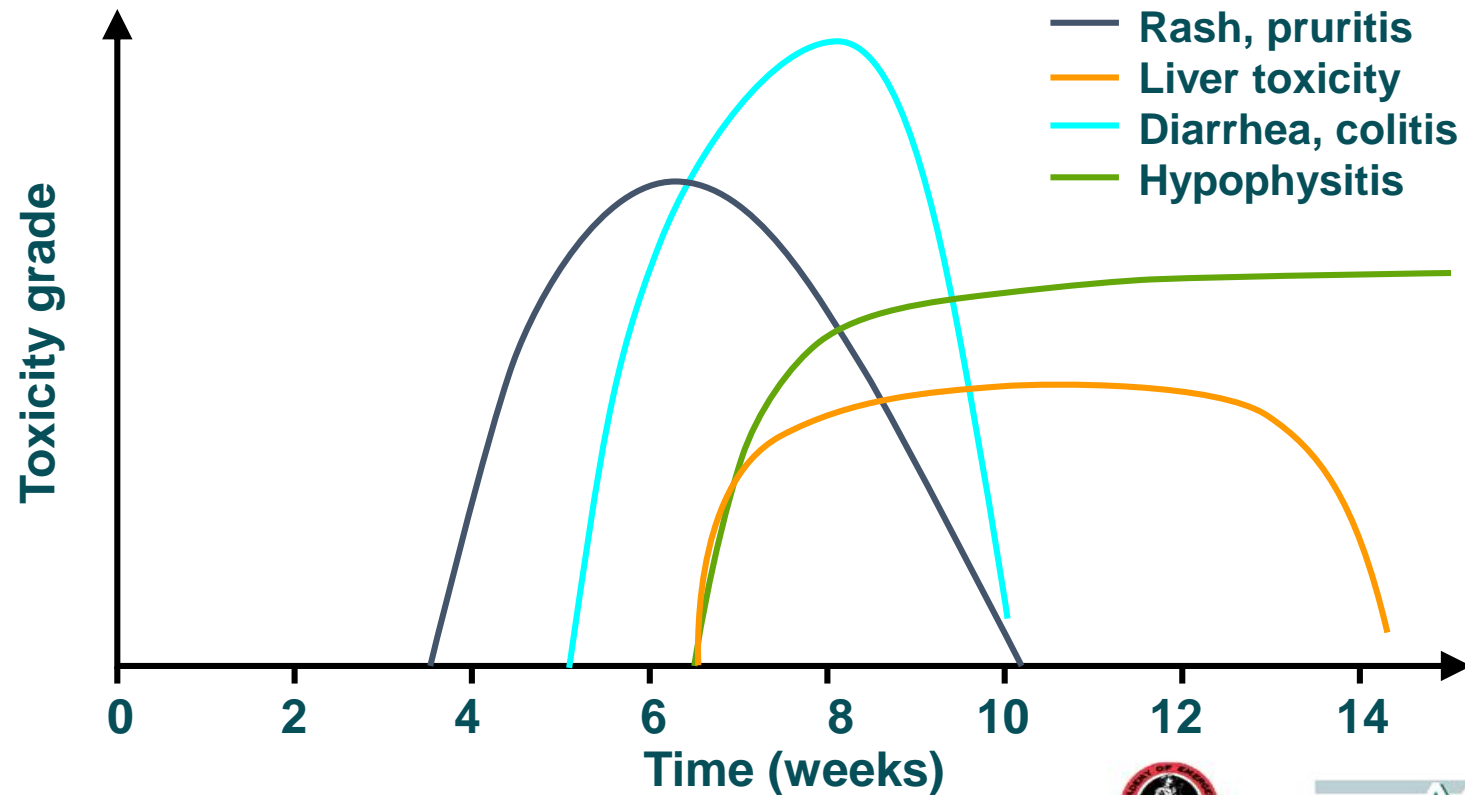
PD-1 Pathway Blockade Based ImmunoRx: Unanswered Questions

- **Will toxicity management prove challenging?**
 - Will rare but serious toxicities occur?
 - **Will late toxicity emerge?**
 - Will certain toxicities make combinations difficult?
 - Will history of autoimmunity limit application?

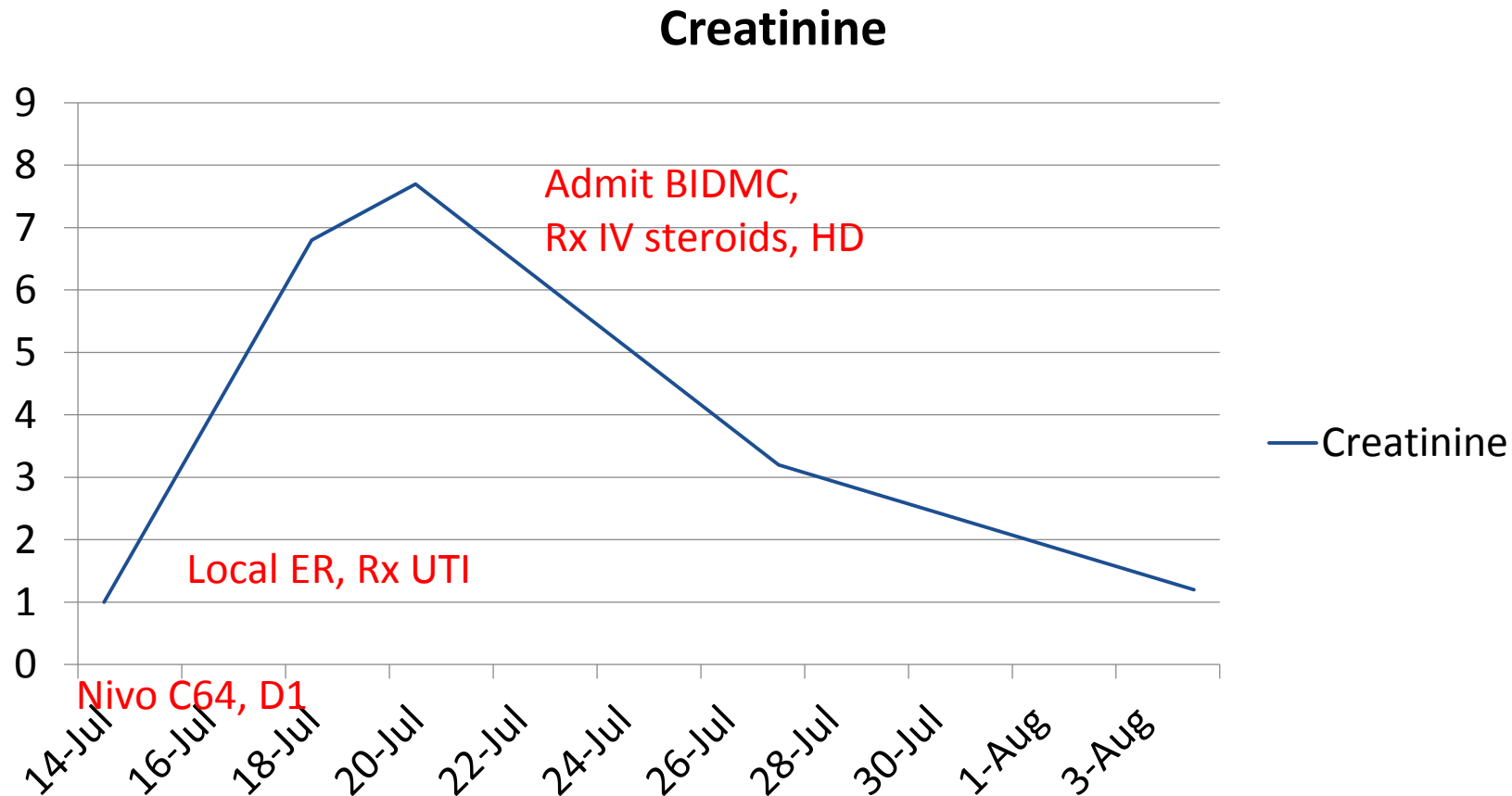


Immune checkpoint inhibitors: immune-related adverse event (irAE) onset

- Each irAE has different kinetics of onset
- Rash first, followed by colitis, hypophysitis and finally hepatitis



Late PD-1 Toxicity?: Acute Renal Failure



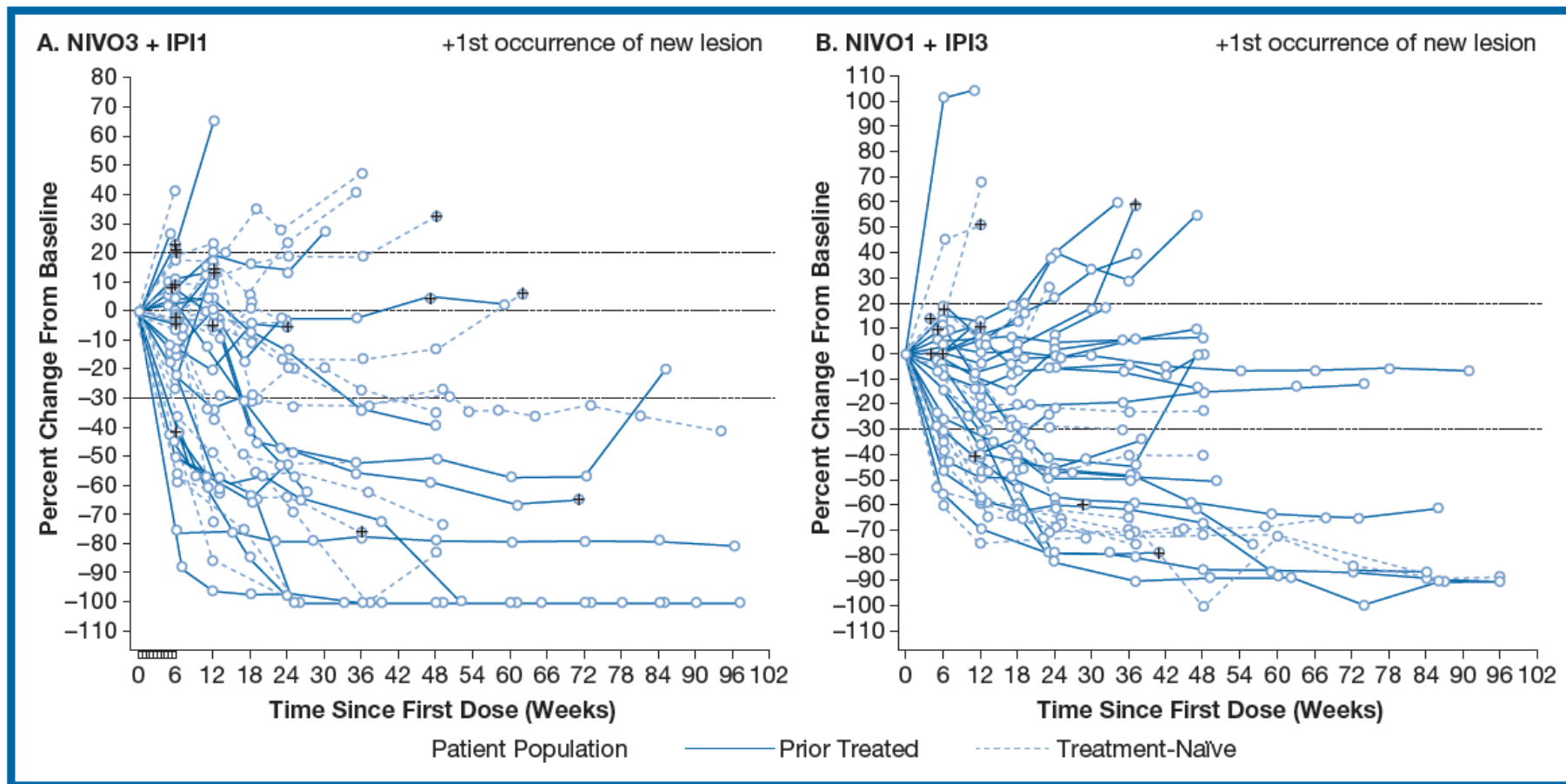
74 yo female, mRCC, s/p sunitinib, enrolled in Nivo P2 trial



PD-1 Pathway Blockade Based ImmunoRx: Unanswered Questions

- **Will toxicity management prove challenging?**
 - Will rare but serious toxicities occur?
 - Will late toxicity emerge?
 - **Will certain toxicities make combinations difficult?**
 - (e.g. nephritis, hepatitis, pneumonitis)
 - Will history of autoimmunity limit application?

PD-1 + CTLA-4 Blockade RCC Results: Tumor burden

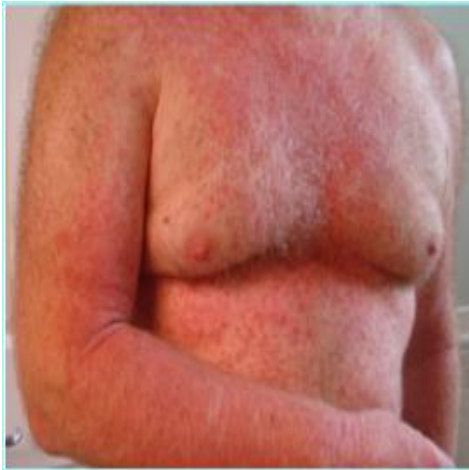

Hammers et al, ASCO 2015



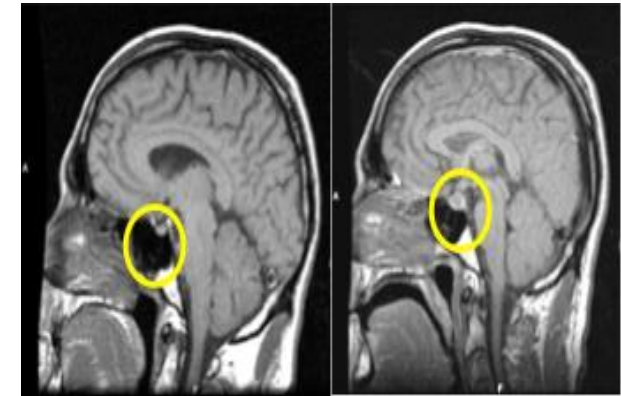
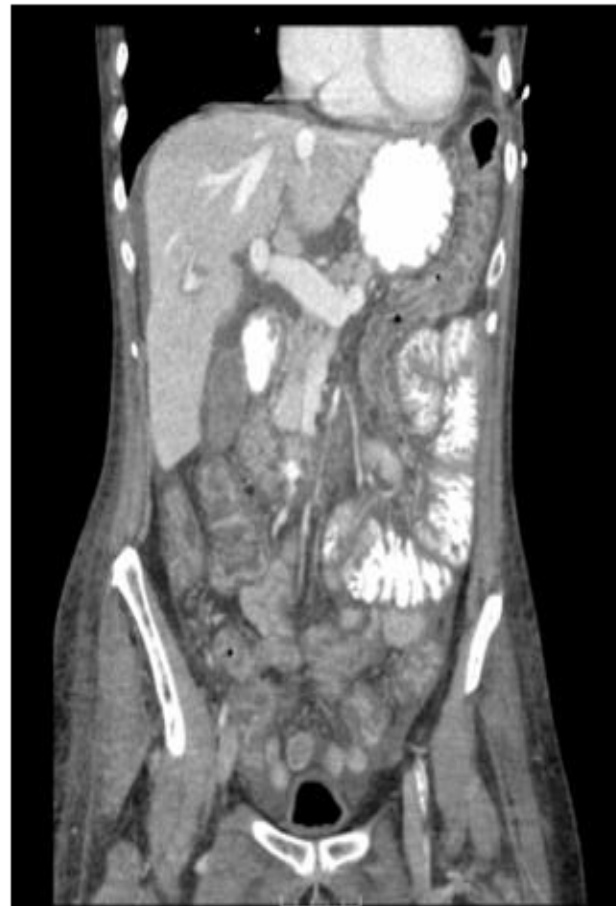

Improving Immune Activation: The Consequences - CTLA4 Antibodies



Dermatitis

Colitis



Hypophysitis



ORIGINAL ARTICLE

Nivolumab and Ipilimumab versus Ipilimumab in Untreated Melanoma

Michael A. Postow, M.D., Jason Chesney, M.D., Ph.D., Anna C. Pavlick, D.O.,
Caroline Robert, M.D., Ph.D., Kenneth Grossmann, M.D., Ph.D., David McDermott, M.D.,
Gerald P. Linette, M.D., Ph.D., Nicolas Meyer, M.D., Jeffrey K. Giguere, M.D.,
Sanjiv S. Agarwala, M.D., Montaser Shaheen, M.D., Marc S. Ernstoff, M.D.,
David Minor, M.D., April K. Salama, M.D., Matthew Taylor, M.D.,
Patrick A. Ott, M.D., Ph.D., Linda M. Rollin, Ph.D., Christine Horak, Ph.D.,
Paul Gagnier, M.D., Ph.D., Jedd D. Wolchok, M.D., Ph.D., and F. Stephen Hodi, M.D.



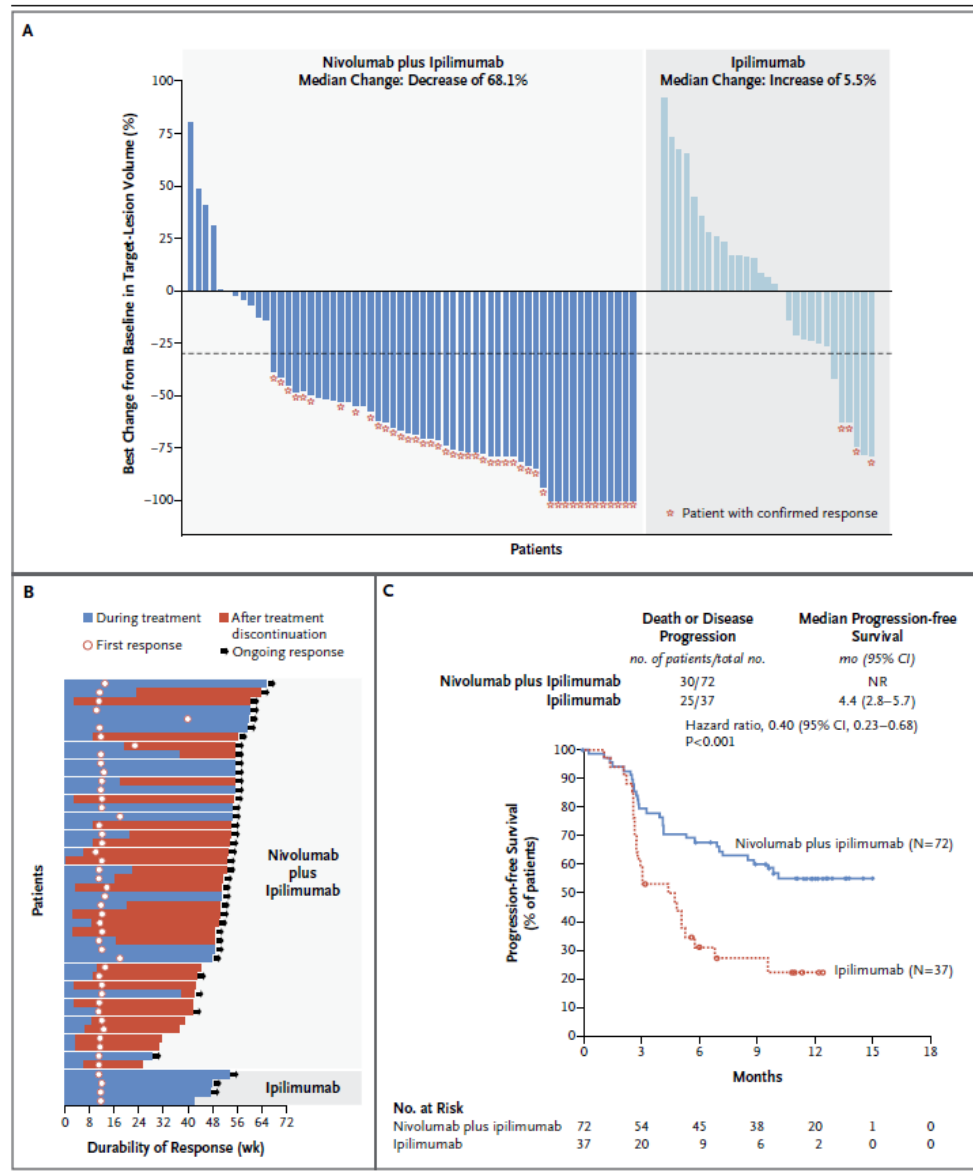


Table 4. Select Adverse Events and Their Management with Immunomodulatory Medication (IMM), According to Organ Category.

Organ Category	Nivolumab plus Ipilimumab (N=94)				Ipilimumab (N=46)			
	Reported Adverse Event	Treatment with IMM	Resolution of Event after Treatment with IMM	Median Time to Resolution	Reported Adverse Event	Treatment with IMM	Resolution of Event after Treatment with IMM	Median Time to Resolution
	<i>no. of patients</i>	<i>no. of patients/total no. (%)</i>	<i>no. of patients/total no. (%)</i>	<i>wk (95% CI)</i>	<i>no. of patients</i>	<i>no. of patients/total no. (%)</i>	<i>no. of patients/total no. (%)</i>	<i>wk (95% CI)</i>
Skin								
Any grade	67	41/67 (61)	24/35 (69)	18.6 (9.3–35.1)	26	13/26 (50)	11/13 (85)	8.6 (3.3–22.0)
Grade 3 or 4	9	9/9 (100)	8/9 (89)	6.1 (0.9–24.1)	0	0	0	NE
Gastrointestinal								
Any grade	48	31/48 (65)	25/28 (89)	4.7 (3.0–6.7)	17	11/17 (65)	7/9 (78)	5.0 (1.4–12.1)
Grade 3 or 4	20	17/20 (85)	15/17 (88)	4.3 (1.4–10.7)	5	5/5 (100)	4/5 (80)	3.6 (0.7–5.0)
Endocrine†								
Any grade	32	14/32 (44)	2/14 (14)	NE (NE–NE)	8	3/8 (38)	1/3 (33)	NE (0.9–NE)
Grade 3 or 4	5	4/5 (80)	1/4 (25)	NE (5.6–NE)	2	2/2 (100)	1/2 (50)	NE (0.9–NE)
Hepatic								
Any grade	26	13/26 (50)	11/13 (85)	14.1 (2.1–19.6)	2	0/2	0	NE
Grade 3 or 4	14	12/14 (86)	10/12 (83)	8.3 (2.1–14.1)	0	0	0	NE
Pulmonary								
Any grade	11	8/11 (73)	6/8 (75)	6.1 (0.3–9.0)	2	2/2 (100)	2/2 (100)	3.2 (2.9–3.6)
Grade 3 or 4	3	3/3 (100)	2/3 (67)	9.0 (0.3–9.0)	1	1/1 (100)	1/1 (100)	3.6 (NE–NE)
Renal								
Any grade	3	2/3 (67)	2/2 (100)	0.4 (0.3–0.6)	1	0/1	0	NE
Grade 3 or 4	1	1/1 (100)	1/1 (100)	0.6 (NE–NE)	0	0	0	NE

PD-1 Pathway Blockade Based ImmunoRx: Unanswered Questions

- **Will toxicity management prove challenging?**
 - Will rare but serious toxicities occur?
 - Will late toxicity emerge?
 - Will certain toxicities make combinations difficult?
 - **Will history of autoimmunity limit application?**

Original Investigation

Ipilimumab Therapy in Patients With Advanced Melanoma and Preexisting Autoimmune Disorders

Douglas B. Johnson, MD; Ryan J. Sullivan, MD; Patrick A. Ott, MD, PhD; Matteo S. Carlino, MBBS;
Nikhil I. Khushalani, MD; Fei Ye, PhD; Alexander Guminski, MD, PhD; Igor Puzanov, MD; Donald P. Lawrence, MD;
Elizabeth I. Buchbinder, MD; Tejaswi Mudigonda, BS; Kristen Spencer, DO; Carolin Bender, MD; Jenny Lee, MBBS;
Howard L. Kaufman, MD; Alexander M. Menzies, MBBS; Jessica C. Hassel, MD; Janice M. Mehnert, MD;
Jeffrey A. Sosman, MD; Georgina V. Long, MBBS; Joseph I. Clark, MD



Ipilimumab Therapy in Patients With Advanced Melanoma and Preexisting Autoimmune Disorders

Table 2. Autoimmune Exacerbations and Grade 3 to 5 Immune-Related Adverse Events

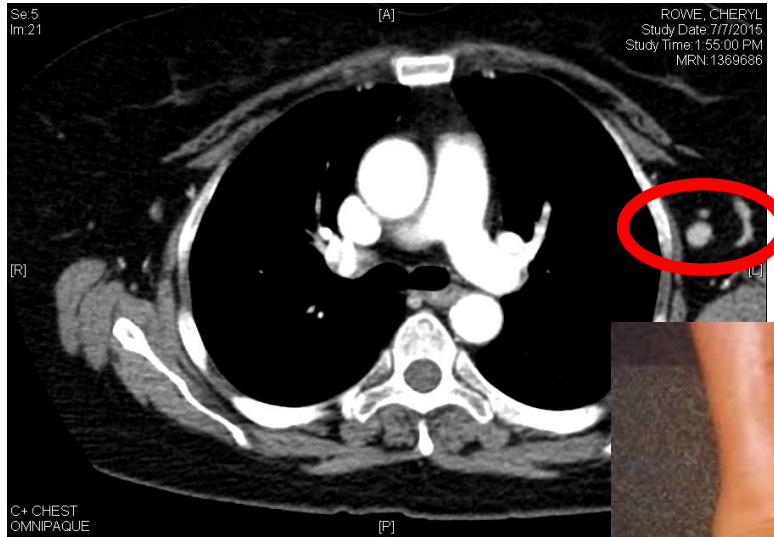
Patient No.	Baseline Condition	Autoimmune Exacerbation	Treatment	Immune-Related Adverse Event	Treatment	Outcome Notes
2	Sarcoidosis	Glaucoma	Ocular steroids	Durable CR
3	RA	Joint pain	As for hypophysitis	Hypophysitis	Prednisone 1 mg/kg tapered over 6 wk; now receiving 7.5 mg	Durable CR
4	RA	Thyroiditis	Prednisone 1 mg/kg tapered over 2 wk	
5	Psoriasis	Worsening plaques	As for colitis	Colitis	Methylprednisolone 2 mg/kg tapered over 6 wk	After 1 dose
6	Psoriasis, Graves disease	Hypophysitis	Prednisone 30 mg ×1 wk, transition to hydrocortisone over 5 d	PR
8	RA, polymyalgia rheumatica	Joint pain, myalgias	Prednisone 30 mg/d tapered over 1 mo	After 3 d
9	RA	Joint pain	Prednisone 15 mg/d down to 10 mg	After 7 mo
11	Transverse myelitis	Colitis	Prednisone 1 mg/kg tapered over 8 wk	
12	Crohn disease	Colitis	Methylprednisolone 1 mg/kg tapered over 8 wk	After 1 dose
14	Ulcerative colitis	Diarrhea, disease flare	Infliximab, dexamethasone 2 mg daily ^a	PR
15	Inflammatory arthritis ^b	Joint pain	As for colitis	Colitis	Prednisone 1 mg/kg tapered over 4 wk, infliximab	...
20	Psoriasis	Hypophysitis	Prednisone 50 mg ×1 dose, then 5 mg daily	...
23	Sarcoidosis	Hypercalcemia, renal insufficiency	Prednisone 25 mg/d, tapered to 20 mg after 4 wk	Ongoing SD
24	RA	Joint pain	Prednisone 10 mg/d, now receiving 8 mg/d	Ongoing PR
28	Psoriasis	Presumed colitis grade 5	Methylprednisolone 1 mg/kg	Patient died

Abbreviations: CR, complete response; ellipses, none; PR, partial response; RA, rheumatoid arthritis; SD, stable disease.

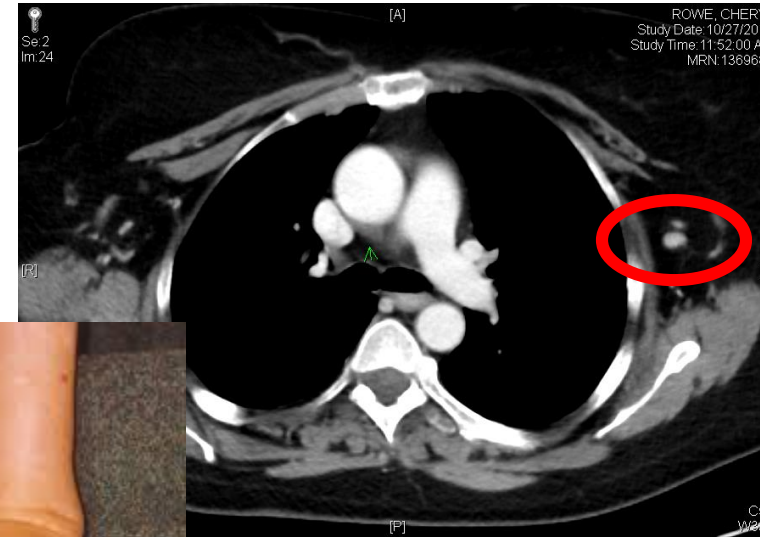
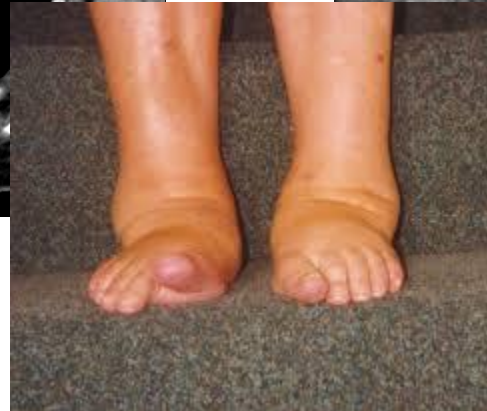^a Receiving dexamethasone for brain metastases; infliximab was added with onset of diarrhea.

^b Patient developed a chronic, inflammatory-appearing arthritis during nivolumab therapy that improved with use of low-dose steroids and hydroxychloroquine.

PD-1 Blockade in Patient with Autoimmune Disease



4/15



10/15

62 y.o. female, met melanoma, psoriatic arthritis S/P HD IL-2
4/15 - PD-1 (pembro) x 4 doses
7/15 – CTs = SD, PA flared, pembrolizumab held, rx – apremilast
10/15 – CT = MR, PA improved, plan = observation



PD-1 Pathway Blockade Based ImmunoRx: Unanswered Questions

- **Will toxicity management prove challenging?**
 - Not to the informed
 - Will rare but serious toxicities occur?
 - YES
 - Will late toxicity emerge?
 - YES
 - Will certain toxicities make combinations difficult?
 - Probably
 - Will history of autoimmunity limit application?
 - Yes, in some cases